

# Index of Suspicion in the Nursery

## 2 Term Female Newborn with Prenatal Diagnosis of Abdominal Distention and Ascites

Kevin Crow, MD,\* Rachel Glad, MD,\* Aisha Venugopal, MD,§  
Jamil H. Khan, MD,<sup>†§</sup> Samantha Vergano, MD,<sup>†§</sup> W. Thomas Bass, MD<sup>†§</sup>

*\*Department of Pediatrics, Eastern Virginia Medical School, Norfolk, VA*

*†Division of Neonatal Medicine, †Division of Medical Genetics and Metabolism,*

*§Department of Pediatrics, Children's Hospital of the King's Daughters, Eastern Virginia Medical School, Norfolk, VA*

### PRESENTATION

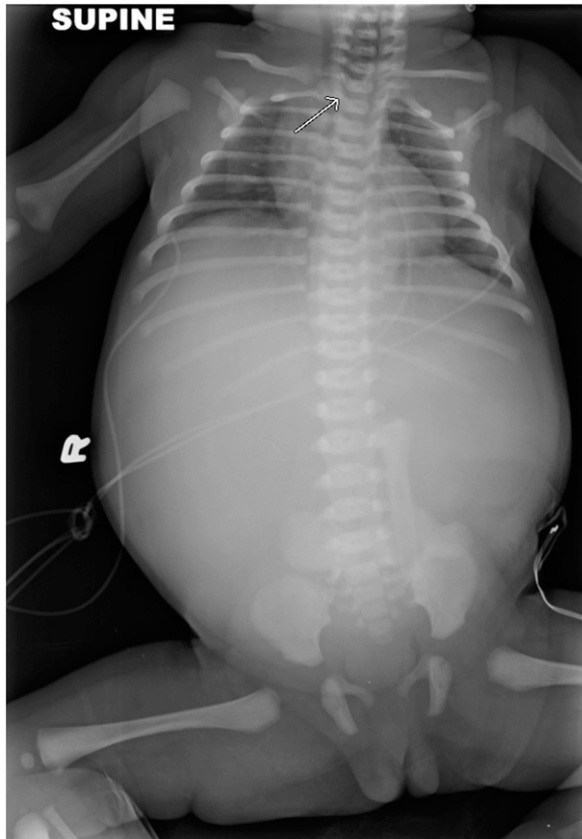
A 3,960-g female infant is born at 37 weeks of gestation to a 25-year-old gravida 2, para 1-0-0-1 woman via vaginal delivery. The pregnancy had been complicated by a history of depression not requiring pharmacologic treatment, a urinary tract infection treated successfully, fetal abdominal distention and ascites, and polyhydramnios requiring 3 procedures for amniotic fluid reduction. Noninvasive prenatal testing and  $\alpha$ -fetoprotein levels were normal.

Apgar scores are 6 and 8 at 1 and 5 minutes, respectively. The infant has decreased respiratory effort but improves with continuous positive airway pressure and is weaned to room air while in the delivery room with no further respiratory concerns. Because of the significant abdominal distention, the patient is transferred to the NICU where the physical examination findings are significant for abdominal distention, an abdominal circumference of 38 cm, palpable bowel loops, and absent bowel sounds. Other significant findings include bilateral webbing of the second and third toes and bilateral fusion of the fourth and fifth toes. The father notes that he has mild bilateral syndactyly of his toes. The head circumference is 32.5 cm (86th percentile). Cardiovascular and respiratory examination findings are normal. The infant has difficulty with excess secretions, therefore, an orogastric tube is placed, and chest and abdominal radiography performed (Fig 1). Chest and abdominal computed tomography (CT) with contrast is performed (Figs 2A, B, C). Further genetic testing reveals the diagnosis.

### DIFFERENTIAL DIAGNOSIS

Neonatal hydrops  
Urinary ascites  
Chylous ascites  
Pancreatic ascites  
Nephrotic syndrome  
Hepatobiliary obstruction  
Meconium peritonitis  
Infectious peritonitis  
Pyloric atresia

**AUTHOR DISCLOSURE** Drs Crow, Glad, Venugopal, Khan, Vergano, and Bass have disclosed no financial relationships relevant to this article. This commentary does not contain a discussion of an unapproved/investigative use of a commercial product/device.

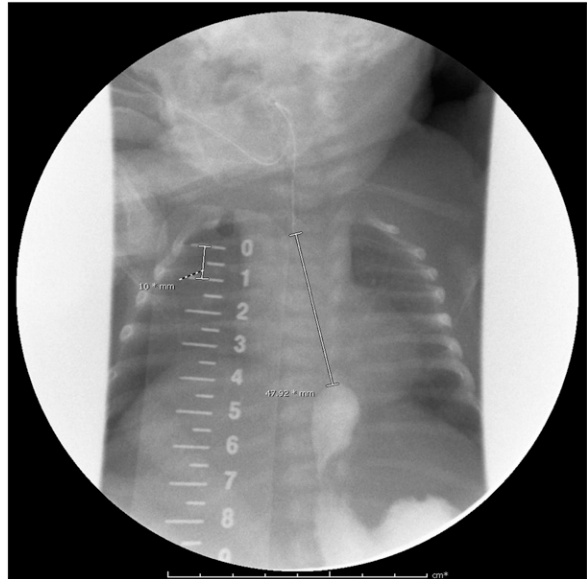


**Figure 1.** The orogastric tube is coiled in a proximal esophageal pouch, suggesting esophageal atresia (arrow); however, the abdomen is distended, airless, and fluid-filled, indicating the absence of a distal tracheoesophageal fistula.

Congestive heart failure  
Rupture of ovarian cyst

### ACTUAL DIAGNOSIS

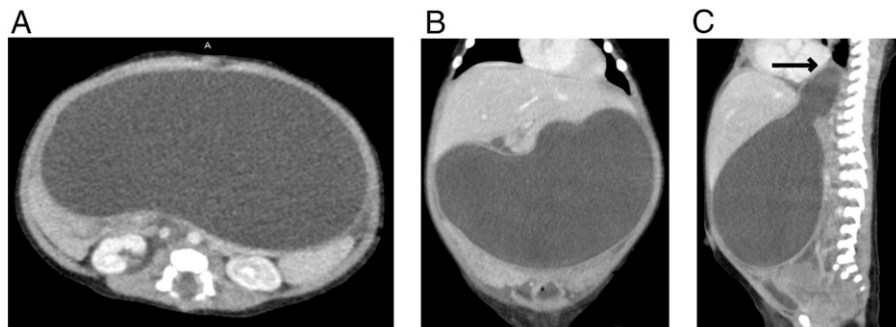
Pyloric atresia, associated with esophageal atresia and abnormal digits—oculo-digito-esophago-duodenal syndrome—Feingold syndrome



**Figure 3.** Contrast study of the esophagus showing the marked distance between the proximal and distal segments.

### THE CONDITION

Feingold syndrome (MIM 164280), also known as *oculo-digito-esophago-duodenal syndrome* (ODED), is a rare autosomal dominant genetic disorder of unknown prevalence or incidence, caused by mutations in the neuroblastoma-derived V-myc avian myelocytomatosis viral-related oncogene (*MYCN*) located on the short arm of chromosome 2 (2p24.1). (1) These mutations are thought to alter specific structural protein function by protein truncation, but the exact mechanism is unknown. Approximately 60% of reported cases of Feingold syndrome have an affected parent and despite being an autosomal dominant disorder, 63% of affected patients are female. Feingold syndrome type 1 is associated with esophageal and duodenal or pyloric atresia, limb malformations, and learning disability associated with microcephaly. (2) Abnormalities of the digits are common



**Figure 2.** A. Axial abdominal computed tomography (CT) scan with contrast. B. Anterior-posterior abdominal CT scan. C. Lateral view of abdomen.

and include brachymesophalangy, thumb hypoplasia, or syndactyly of toes which is typically seen between the second and third toes and between the fourth and fifth toes. Feingold syndrome type 2 is similar in appearance but lacks intestinal anomalies.

The initial chest radiograph of our patient (Fig 1) showed the orogastric tube coiled in the proximal esophagus with an airless, fluid-filled, distended abdomen. These findings indicated the presence of esophageal atresia without tracheo-oesophageal fistula. Chest and abdominal CT with contrast (Fig 2) demonstrated esophageal atresia and an excessive amount of fluid in a distended stomach or bowel, suggesting pyloric versus duodenal/jejunal atresia. The infant was taken to the operating room on day 3 and underwent gastric fluid aspiration of 0.5 L, gastrojejunostomy with gastrostomy tube placement, and appendectomy. Examination of the bowel confirmed the presence of pyloric atresia along with malrotation. Because of the unusual constellation of gastrointestinal abnormalities, the genetics department was consulted on day 3; microarray testing was recommended, which demonstrated the R373X variant of the *MYCN* gene. No parental testing was performed. On day 20, contrast studies were performed and determined the length of the esophageal defect to be between 4.8 and 6.1 cm (Fig 3).

Because of the distance between the proximal and distal esophageal segments, surgical repair of the esophagus was delayed for 18 weeks. A leak at the repair site delayed the

initiation of enteral feedings for another 9 weeks. Since that time, enteral feeds have been tolerated well and the infant was discharged from the hospital at a postnatal age of 28 weeks with bolus feedings via a gastrostomy tube.

#### Lessons for the Clinician

Although atretic lesions of the neonatal gastrointestinal system are common and generally isolated, multiple areas of atresia should alert the clinician to look for genetic causes.

## American Board of Pediatrics Neonatal-Perinatal Content Specification

- Know when to obtain karyotypes on the subject, parents, or other family members.

## References

1. Tészás A, Meijer R, Scheffer H, et al. Expanding the clinical spectrum of *MYCN*-related Feingold syndrome. *Am J Med Genet A*. 2006;140(20):2254–2256
2. Celli J, van Bokhoven H, Brunner HG. Feingold syndrome: clinical review and genetic mapping. *Am J Med Genet A*. 2003;122A(4):294–300

## Case 2: Term Female Newborn with Prenatal Diagnosis of Abdominal Distention and Ascites

Kevin Crow, Rachel Glad, Aisha Venugopal, Jamil H. Khan, Samantha Vergano and W. Thomas Bass

*NeoReviews* 2020;21:e483  
DOI: 10.1542/neo.21-7-e483

<b>Updated Information &amp; Services</b>	including high resolution figures, can be found at: <a href="http://neoreviews.aappublications.org/content/21/7/e483">http://neoreviews.aappublications.org/content/21/7/e483</a>
<b>References</b>	This article cites 2 articles, 0 of which you can access for free at: <a href="http://neoreviews.aappublications.org/content/21/7/e483.full#ref-list-1">http://neoreviews.aappublications.org/content/21/7/e483.full#ref-list-1</a>
<b>Subspecialty Collections</b>	This article, along with others on similar topics, appears in the following collection(s): <b>Pediatric Drug Labeling Update</b> <a href="http://classic.neoreviews.aappublications.org/cgi/collection/pediatric_drug_labeling_update">http://classic.neoreviews.aappublications.org/cgi/collection/pediatric_drug_labeling_update</a>
<b>Permissions &amp; Licensing</b>	Information about reproducing this article in parts (figures, tables) or in its entirety can be found online at: <a href="https://shop.aap.org/licensing-permissions/">https://shop.aap.org/licensing-permissions/</a>
<b>Reprints</b>	Information about ordering reprints can be found online: <a href="http://classic.neoreviews.aappublications.org/content/reprints">http://classic.neoreviews.aappublications.org/content/reprints</a>



**Case 2: Term Female Newborn with Prenatal Diagnosis of Abdominal Distention and Ascites**

Kevin Crow, Rachel Glad, Aisha Venugopal, Jamil H. Khan, Samantha Vergano and W. Thomas Bass

*NeoReviews* 2020;21:e483  
DOI: 10.1542/neo.21-7-e483

The online version of this article, along with updated information and services, is located on the World Wide Web at:

<http://neoreviews.aappublications.org/content/21/7/e483>

Neoreviews is the official journal of the American Academy of Pediatrics. A monthly publication, it has been published continuously since 2000. Neoreviews is owned, published, and trademarked by the American Academy of Pediatrics, 141 Northwest Point Boulevard, Elk Grove Village, Illinois, 60007. Copyright © 2020 by the American Academy of Pediatrics. All rights reserved. Online ISSN: 1526-9906.

**American Academy of Pediatrics**

DEDICATED TO THE HEALTH OF ALL CHILDREN®

