

# Robot-Assisted Surgery for Upper Tract Urothelial Carcinoma



Eric M. Lo, BS<sup>a</sup>, Hyung L. Kim, MD<sup>b,\*</sup>

## KEYWORDS

- Cancer • Transitional cell carcinoma • Urothelial carcinoma • Upper tract • Robotic surgery
- Ureterectomy

## KEY POINTS

- Upper tract transitional cell carcinoma is a rare malignancy for which surgery is the only definitive treatment.
- Robot-assisted surgery provides a minimally invasive approach and has become more popular in recent years.
- Robot-assisted techniques for upper tract urothelial carcinoma seem to have similar outcomes to open and laparoscopic approaches.
- For select ureteral cancers, the involved kidney can be spared by performing robot-assisted distal ureterectomy or segmental ureterectomy.

## INTRODUCTION AND BACKGROUND

Upper tract urothelial carcinoma (UC), also referred to as upper tract transitional cell carcinoma, is a rare disease that makes up approximately 5% of all UCs and less than 5% to 7% of all renal tumors.<sup>1</sup> Upper tract UC is two times more common in men than in women and is commonly diagnosed in the eighth decade of life.<sup>2</sup> The disease is often multifocal at presentation because the entire urothelial surface has been exposed to urinary carcinogens resulting in a “field cancerization” effect.<sup>3</sup> Staging of upper tract UC is based on the tumor, node, metastasis (TNM) system.<sup>4</sup> In the eighth edition of the staging system, stage IV cancers have metastasized to the lymph nodes or distant sites.<sup>5</sup> Lower stages are categorized by the invasiveness of the primary tumor. Stage 0a and 0is refer to tumors that are papillary and noninvasive carcinoma (Ta), and carcinoma in situ (Tis), respectively. Stages 1 to 3 correspond to T1, T2, and T3 tumor

categories, with each category representing an increase in tumor invasiveness. Survival correlates with tumor stage at diagnosis, with 5-year survival rates of 100% for stage Ta and Tis versus 41% for stage T3 disease.<sup>6</sup> Surgery is considered the only definitive treatment for upper tract UC. Historically, open nephroureterectomy was considered the treatment of choice. However, technological developments have ushered in newer, minimally invasive techniques, such as laparoscopic nephroureterectomy and robot-assisted laparoscopic nephroureterectomy. Clayman and colleagues described the first laparoscopic nephroureterectomy in 1991, and subsequent reports demonstrated comparable oncologic outcomes with reduced morbidity when compared with open surgery.<sup>7,8,9</sup> The first robot-assisted nephrectomy was reported in 2000, and the robotic platform rapidly grew in popularity for numerous urologic procedures in the following two decades.<sup>10,11</sup> Robot-assisted nephroureterectomies demonstrated comparable

<sup>a</sup> Baylor College of Medicine, 1 Baylor Plaza, Houston, TX 77030, USA; <sup>b</sup> Cedars-Sinai Medical Center, 8635 West Third Street, Los Angeles, CA 90048, USA

\* Corresponding author.

E-mail address: [kimhl@csmc.edu](mailto:kimhl@csmc.edu)

clinical outcomes to laparoscopic and open approaches, and were also associated with the shortest hospital stays.<sup>12</sup> Increased use of robot-assisted surgeries can be attributed to improved dexterity provided by the da Vinci surgical system (Intuitive Surgical, Sunnyvale, CA), increased use of minimally invasive techniques in training programs, and increased availability of the robot platform.<sup>13</sup> Techniques, such as distal ureterectomy with ureteral reimplant, which has the advantage of sparing both kidneys, can be performed using the robotic platform. Segmental ureterectomy with primary ureteroureterostomy is an additional method of managing upper tract UC and also can be performed robotically. Compared with open surgery, robot-assisted surgery offers the advantage of improved cosmesis and shorter recovery.<sup>14</sup>

## OUTCOMES

Historically, open radical nephroureterectomy was considered the gold standard for definitive treatment of upper tract UC.<sup>15</sup> Technological developments led to laparoscopic and robot-assisted techniques in the management of upper tract UC. With the increased dexterity offered by the da Vinci surgical system, minimally invasive approaches have become more widely available. Although the robotic approach has not been evaluated in prospective, randomized trials, retrospective data show cancer control outcomes that are similar to open and laparoscopic approaches. Clements and colleagues<sup>12</sup> performed a comparative survival analysis of 3801 patients undergoing robot-assisted versus laparoscopic or open surgery for upper tract UC and found that robotic surgery was associated with the shortest length of hospital stay with no difference in readmission rates, overall, or cancer-specific survival (CSS) rates. De Groote and colleagues<sup>16</sup> performed a retrospective review from three high-volume centers for robotic surgery and assessed perioperative, pathologic, and oncologic outcomes. They concluded that robot-assisted nephroureterectomy is safe and feasible, has low postoperative morbidity, is rarely associated with major complications, and has acceptable oncologic outcomes.<sup>16</sup> Lenis and colleagues<sup>17</sup> identified 3116 patients in the National Cancer Database and evaluated whether choice of surgical approach had any effect on decision to perform lymph node dissection, lymph node yield, and overall survival. The authors concluded that compared with open nephroureterectomy, robot-assisted nephroureterectomy did not compromise performance of a lymphadenectomy and that robot-assisted

nephroureterectomy may actually be associated with improved lymph node yield.<sup>17</sup>

Robotic surgery provides dexterity to perform minimally invasive reconstructive surgeries that can preserve the kidney. Therefore, it is relevant to review the data supporting the safety and efficacy of kidney-sparing surgeries, such as distal ureterectomy with ureteral reimplant and segmental ureterectomy with primary ureteroureterostomy. Fukushima and colleagues<sup>18</sup> retrospectively reviewed a multi-institution database of 1329 patients treated for upper tract UC and found that there was no statistically significant difference in CSS and recurrence-free survival between the distal ureterectomy and nephroureterectomy, even when patients were stratified by tumor stage. Dalpiaz and colleagues<sup>19</sup> performed a retrospective chart review of 49 patients who underwent distal ureterectomy and 42 patients who underwent radical nephroureterectomy. Notably, both high- and low-grade cancers were represented in both treatment groups. The authors found that CSS and recurrence-free survival at 5 years did not differ significantly between the two groups. Jeldres and colleagues<sup>20</sup> compared the outcomes of segmental ureterectomy with nephroureterectomy in an analysis of 2044 patients and found no significant differences in cancer-specific mortality rates at 5 years. Seisen and colleagues<sup>21</sup> performed a meta-analysis comparing segmental ureterectomy with nephroureterectomy and found no significant differences in CSS between the two groups at 3 years, 5 years, or last follow-up.

## PREOPERATIVE WORK-UP

Patients with upper tract UC often present with hematuria as the first clinical sign of disease, with gross or microscopic hematuria found in 70% to 80% of patients at time of diagnosis. Flank pain secondary to ureteral obstruction caused by a mass is another common presenting symptom and occurs in approximately 20% of patients.<sup>22</sup> Physical examination may reveal a flank mass in a rare cases. Imaging is critical to diagnosing upper tract UC. Computed tomography urography is the most accurate imaging technique for diagnosing upper tract UC with a reported sensitivity of 0.97 and specificity of 0.93.<sup>23</sup> In patients who cannot undergo computed tomography, MRI can be performed. The sensitivity of magnetic resonance urography is 0.75 for detecting tumors less than 2 cm.<sup>22</sup> Urine cytology and cystoscopy provide additional means of evaluating the urothelium. Positive urine cytology with negative cystoscopy is highly suggestive of upper tract UC and

further evaluation with upper tract imaging is critical. However, it is important to keep in mind that cytology from the bladder is less sensitive for upper tract UC when compared with UC of the bladder, and Messer and colleagues<sup>24</sup> recommended that when upper tract UC is suspected, cytology be performed using samples obtained directly from the renal cavities. Fluorescence in situ hybridization is commonly used in the diagnosis of bladder cancer, but like urine cytology, has a limited role in upper tract UC. Diagnostic ureteroscopy provides direct visualization and allows for sampling from the renal pelvis for urine cytology. Furthermore, flexible ureteroscopy allows biopsies to be taken from suspicious lesions and is critical in diagnosing upper tract UC. When considering kidney-sparing surgery for ureteral cancer, it is critical to visually inspect the upper tract and ensure that there is no visible disease in the portion of the urothelial being spared.

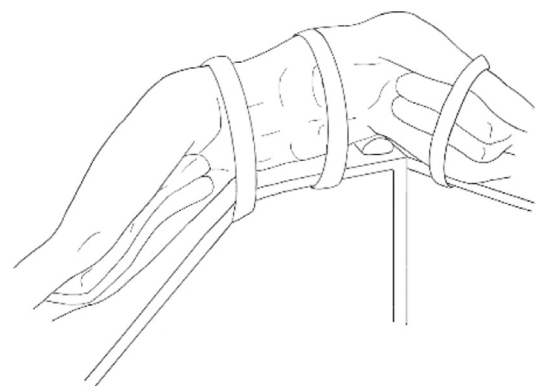
Following appropriate clinical assessment and diagnosis, the urologist must decide on the optimal treatment strategy. Surgery is the only definitive treatment for nonmetastatic upper tract UC and open, laparoscopic, and robot-assisted approaches have all been found to be equally effective for controlling the cancer.<sup>12</sup> Although not the focus of this article, ablative therapies are appropriate for some small UCs. Compared with open surgery, minimally invasive techniques result in lower morbidity, but the use of these techniques ultimately depends on surgeon expertise. Nephroureterectomy has long been the gold standard. However, in carefully selected patients with disease localized to the ureter, segmental ureterectomy is a viable alternative.<sup>20</sup> Distal ureterectomy with reimplantation of the ureter is ideal for patients with low-grade disease in the distal ureter. Overall, kidney-sparing surgery should be strongly considered in patients with normally functioning kidneys with low-grade disease, or in patients with solitary kidney and/or impaired renal function.

Ureteral stents can promote periureteral inflammation, making surgery more challenging. Therefore, if a ureteral stent is present, it can be removed 3 to 7 days before the procedure; however, in patients with symptomatic ureteral obstruction this may not be possible. A urine culture should be strongly considered preoperatively and culture-specific antibiotics given at least 3 to 5 days before surgery, because these patients are more susceptible to becoming septic during the perioperative period. Historically, bowel preparation to decompress the colon was routinely performed; however, the surgery can be safely performed without a formal bowel preparation.

The role of neoadjuvant and adjuvant chemotherapy has not been definitively defined for upper tract UC. For stage II-IIIa bladder cancer, neoadjuvant chemotherapy has been shown to improve survival.<sup>25,26</sup> Therefore, it is reasonable to consider neoadjuvant chemotherapy in select patients with high-grade upper tract disease, particularly if imaging suggests at least stage II disease. Another important consideration is the benefit of neoadjuvant chemotherapy for bladder cancer that has been associated with cisplatin-based chemotherapy, which requires adequate renal function. Therefore, some patients may have adequate renal function to tolerate neoadjuvant chemotherapy but not adjuvant chemotherapy.

### ROBOT-ASSISTED NEPHROURETERECTOMY

Radical nephroureterectomy involves removal of the kidney and ureter along with bladder cuff excision and is recommended for UC of the renal pelvis and upper ureter. The patient is positioned in a lateral decubitus position with the umbilicus at the level of kidney rest. The surgical table is partly flexed to open the space between the thorax and hip. An axillary role is placed two fingerbreadths below the axilla. A gel roll is placed against the back to keep patients in a 45° to 90° flank position. Three-inch cloth tape may be strapped across the upper chest and hip to help secure the patient (Fig. 1). The contralateral, lower arm should be placed on an arm board, supported by foam and loosely secured to the arm board with tape. The ipsilateral arm should be loosely secured with tape to an arm rest, which may be composed of pillows stacked on top of the lower arm. After the patient has been secured to the operating table, the abdomen and flank are shaved, prepared, and draped in standard sterile fashion.



**Fig. 1.** Positioning of patient on table for robot-assisted nephroureterectomy.

The robot provides the greatest advantage when performing the distal ureterectomy and bladder repair. With older generations of the da Vinci robot, such as the da Vinci S and Si, it was often necessary to dock the robot separately for the nephrectomy and the distal ureterectomy. To avoid having to dock twice, it was often simpler to perform the nephrectomy laparoscopically and dock the robot for the distal ureterectomy. However, with the da Vinci Xi, it is possible to dock the robot once because the robotic arms have greater mobility.

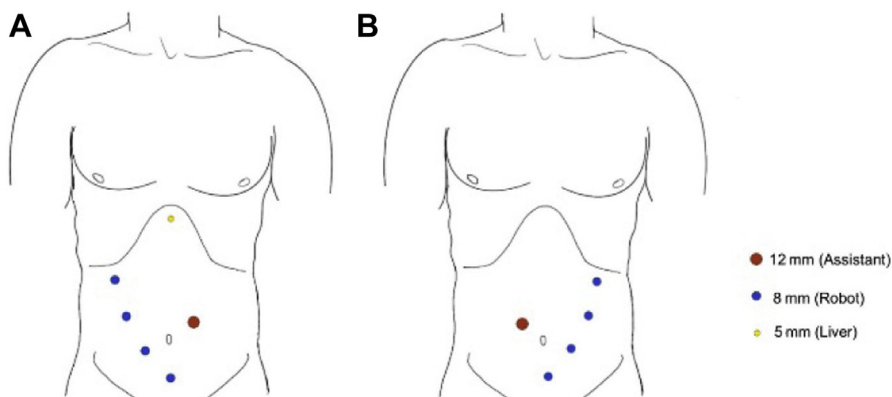
Pneumoperitoneum is established using any variety of techniques. **Fig. 2** shows the port placement for a left nephroureterectomy using the da Vinci Xi. It is often helpful to plan port placement after establishing pneumoperitoneum, which can distend the abdominal wall. The camera port should be placed superior to the umbilicus and immediately lateral to the rectus muscle. The fourth arm is the inferior-most port and care should be taken to avoid inadvertently entering the bladder. A 12-mm assistant port is required. All trocars should be placed under vision if possible. For a right-sided nephroureterectomy, an additional 5-mm port is placed in the midline, just below the xyphoid and used to retract the liver (**Fig. 2**).

Access to the retroperitoneum is gained via incision lateral to the colon along the white line of Toldt.<sup>27</sup> Excision of this avascular tissue lateral to the colon allows the colon to then be reflected medially, providing access to the retroperitoneum. Depending on the laterality of the nephroureterectomy, either the spleen or the liver must then be manipulated. For a left-sided nephroureterectomy, the spleen is mobilized after excision of its lateral attachments. If the spleen is sufficiently mobilized, it will remain off the kidney during the remaining

dissection without having to apply any instruments to the spleen. For a right-sided nephroureterectomy a blunt, locking grasper is inserted through the 5-mm trocar below the xyphoid to lift the liver and lock onto the abdominal wall near the lateral attachment of the liver. The duodenum is also mobilized and deflected medially to provide exposure to the inferior vena cava and renal hilum.

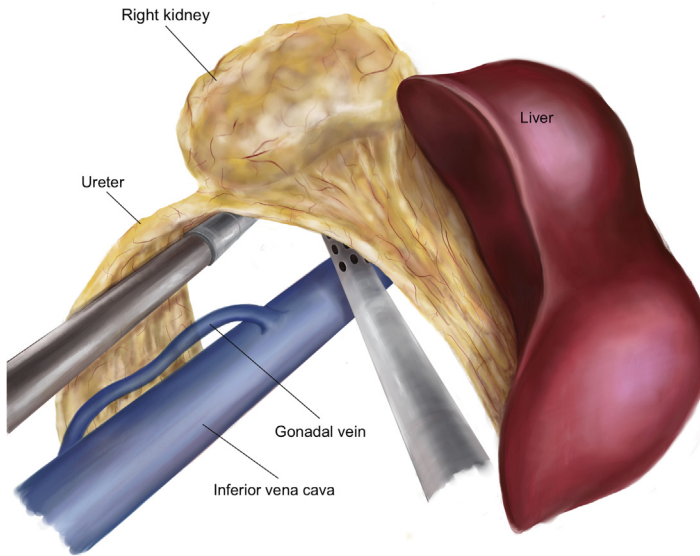
Attention is then directed toward the lower pole of the kidney where the ureter and gonadal vein can be readily identified (**Fig. 3**). The ureter should be identified as early as possible so that a locking clip can be placed below the tumor to prevent distal seeding of cancer during manipulation of the kidney. The ureter is superiorly retracted as the dissection is continued to the hilum. The renal vein should be clearly identified and separated from tissue posterior to the vein, which is expected to contain the renal artery. A laparoscopic vascular stapler can be used to staple and cut the artery and vein separately (**Fig. 4**). Using this approach, it is not necessary to completely mobilize and visualize the renal artery as long as the renal vein has been lifted off the structures immediately posterior to it and hilar tissue containing the artery has been thinned out sufficiently to accommodate the laparoscopic vascular stapler. The adrenal gland should be spared. On the left, the adrenal vein should be visualized, and care should be taken to divide the renal vein distal to the adrenal vein.

The importance of performing a retroperitoneal lymph node dissection (RPLND) has not been established. However, it is likely that an RPLND will improve nodal staging and help determine prognosis.<sup>28</sup> During an RPLND, bulky nodes and nodes visible on preoperative imaging should be prioritized for removal. A complete nodal dissection may include the retroperitoneal package extending from the crus of the diaphragm down



**Fig. 2.** Port placement for robot-assisted nephroureterectomy. (A) Right-sided port placement. (B) Left-sided port placement.

**Fig. 3.** Identification of ureter and gonadal vein at lower pole of kidney during a right-sided nephroureterectomy.

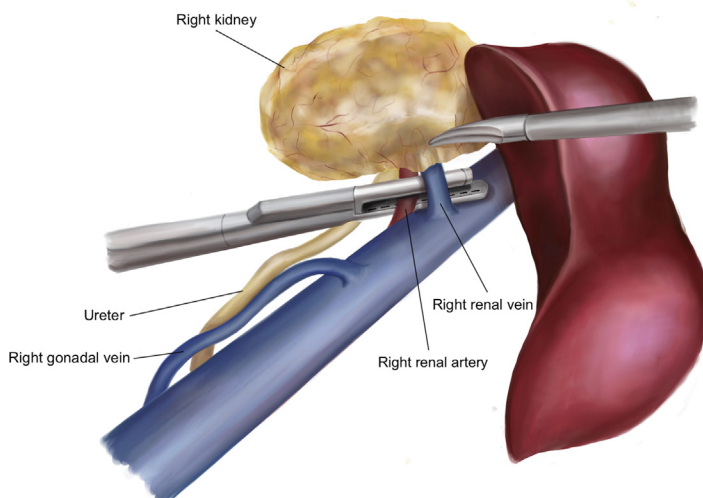


to pelvic nodes. However, the template can be modified based on the location of the tumor. For a left renal pelvis tumor, our practice is to perform an RPLND using the following structures to define the template: crus of the diaphragm, the left ureter, the aortic bifurcation, and the vena cava. For a right renal pelvis tumor, the following structures define our template: crus of the diaphragm, the right ureter, bifurcation of the vena cava, and aorta. Patients undergoing RPLND are at risk for developing a chyle leak. Therefore, all lymphatic vessels should be clipped using metal clips before

being divided. The assistant can apply the clips using a multifire laparoscopic clip applicator.

The goal is to remove kidney, ureter, and bladder cuff en bloc. To complete the distal ureterectomy and bladder cuff excision, the ureter is traced down to its entry into the bladder. Before doing this, it is helpful to move the three working robotic trocars from the top three 8-mm trocars to the bottom three 8-mm trocars. While tracing the ureter, the vas deferens should be ligated where it crosses the ureter anteriorly. As dissection of the ureter is continued distally, the

**Fig. 4.** Exposure of vessels of renal hilum during robot-assisted nephroureterectomy.





obliterated umbilical artery and bladder pedicles are encountered lateral and perpendicular to the course of the ureter (Fig. 5). These structures should be divided between Hem-o-lok clips to facilitate the ureteral dissection. When the detrusor is encountered, 2-cm incisions are made at the 12- and 6-o'clock positions. This should expose the underlying mucosal layer. A full-thickness apical stitch is placed at the top of this incision. The mucosal layer can be pulled into the surgical field by gently pulling on the ureter. This facilitates resection of the bladder cuff and helps identify the mucosal layer for the subsequent bladder closure (Fig. 6). Care should be taken to avoid damaging the contralateral ureter. The bladder is closed in two layers with a 2-0 polyglactin 910 barbed stitch placed in a running fashion. A leak test is performed through a urethral catheter. A Foley catheter should remain in place for approximately 1 week; however, if the patient passes the intraoperative leak test, some surgeons remove the Foley catheter as early as post-operative Day 1. The 12-mm assist port may be used to insert a specimen bag and the specimen may be removed through a Pfannenstiel incision. It should be noted that the distal ureterectomy and bladder repair can be performed before the nephrectomy and this provides the advantage of keeping the kidney and upper ureter in their

orthotopic position, allowing more tension to be applied to the ureter.

### ROBOT-ASSISTED DISTAL URETERECTOMY WITH REIMPLANT

Although nephroureterectomy is considered the gold standard for treatment of upper tract UC, kidney-sparing surgery may be considered in patients with distal ureteral tumors, particularly when renal function is compromised. The preoperative evaluation must include ureteroscopy of the proximal collecting system that will be preserved to ensure that this portion of the urothelium is free of visible cancer. Uberoi and colleagues<sup>29</sup> first described the robot-assisted distal ureterectomy with ureteral reimplantation and since then, various retrospective studies have compared distal ureterectomy with nephroureterectomy, and identified similar outcomes.

For surgery, the patient is placed supine and near-maximum Trendelenburg position. Foam pads should be placed under all pressure points and the surgeon should verify that the patient is secured to the operating table. A urinary catheter is inserted into the bladder, which is drained after the balloon is inflated. Once positioned, the abdomen is shaved, prepared, and draped in standard sterile fashion. Pneumoperitoneum is achieved with Veress needle. Five to six robotic

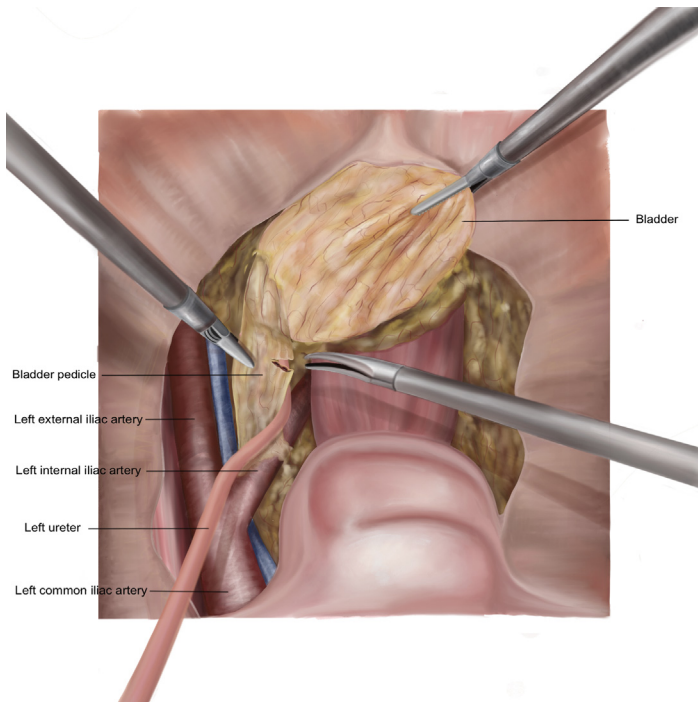
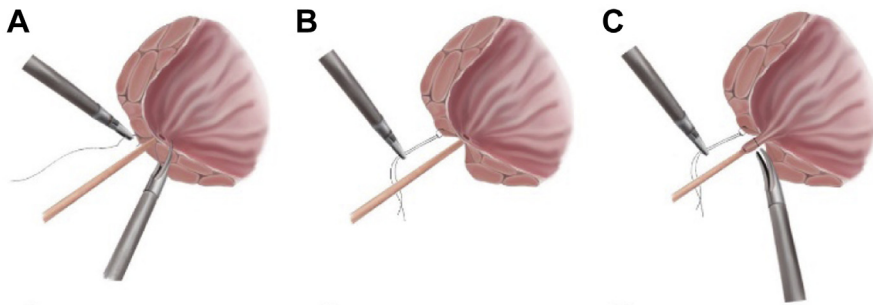


Fig. 5. Exposure of distal ureter during nephroureterectomy.



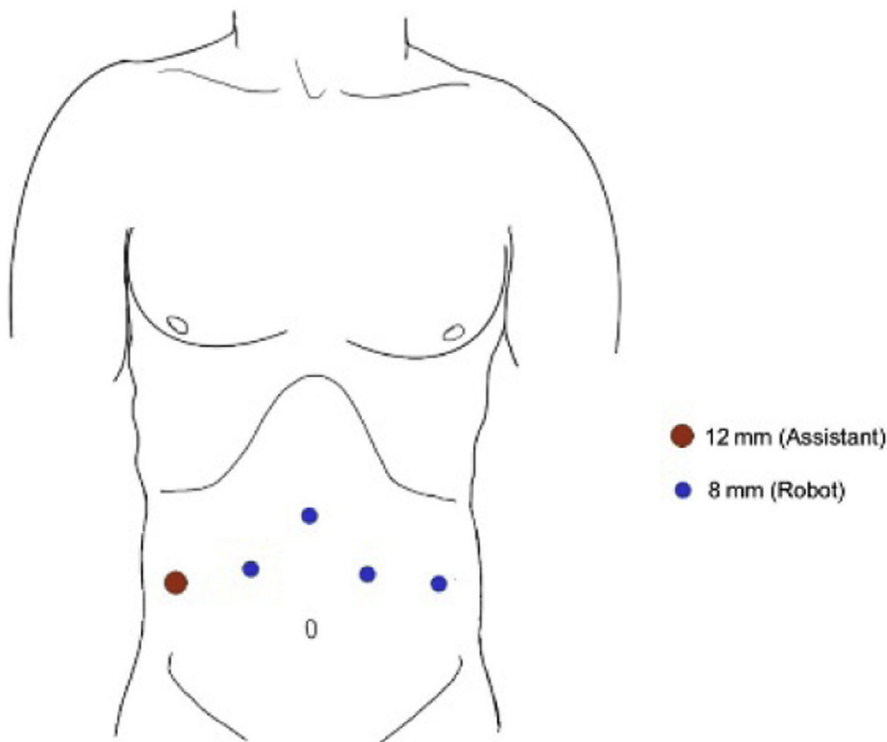
**Fig. 6.** Bladder cuff excision during nephroureterectomy. (A, B) Placement of a holding stitch into the detrusor muscle. (C) Tenting of the bladder mucosa before incision.

arm ports are placed (Fig. 7). The robot is then docked along the side of the bed.

In most cases, the ureteral tumor should be identifiable based on a bulging appearance. Pre-operative imaging should provide additional guidance on location of the tumor. However, for smaller masses where no appreciable mass may be detected via the robotic scope, a ureteroscope may be used. In these cases, a guidewire is placed cystoscopically and advanced to the renal pelvis before docking. During the robotic portion of the case, a ureteroscope is introduced and advanced

over the guidewire to the level of the tumor. At this point, the light from the ureteroscope should be visible laparoscopically and help the surgeon localize the tumor.<sup>30</sup>

Once the robot is fully docked, the surgeon should mobilize the colon to access the retroperitoneum. The ureter should be identified, and the distal ureter should be dissected along with a cuff of bladder. The ureteral lesion should be identified, and the ureter tied off or clipped proximal and distal to the tumor to prevent tumor spillage. When dissecting the distal ureter, the vas deferens



**Fig. 7.** Port placement for distal ureterectomy.

(round ligament in women), obliterated umbilical artery, and bladder pedicle are divided between Hem-o-lok clips. The bladder detrusor is then incised and opened adjacent to the ureter. A retracting stitch can be placed in the bulging mucosa, just inside the detrusor, or in the full thickness of the bladder to help provide traction during subsequent bladder closure. The bladder cuff is excised circumferentially around the ureteral orifice. The ureter is divided proximal to the ureteral tumor and the proximal margin of the ureter is sent for frozen section analysis. Because of the small size of most ureteral tumors, a specimen retrieval bag is usually not required. The specimen may be removed through a trocar, but if the trocar needs to be removed to enlarge the incision, a specimen bag should be used to prevent tumor spillage and port-site seeding by tumor. The bladder is then closed with a 2-0 polyglactin 910 barbed suture. A pelvic lymph node dissection is performed within the borders of the genitofemoral nerve, aortic bifurcation, obturator nerve, and lymph node of Cloquet. Following confirmation from frozen section analysis that the proximal ureteral margin is negative, the surgeon can prepare for ureter reimplantation.

The surgeon first removes the previously placed clip on the ureter and then proceeds to spatulate the ureter for approximately 1.5 cm using robotic Potts scissors. Next, the bladder is dropped from the abdominal wall by incising the peritoneum lateral to the obliterated umbilical ligaments and dividing the obliterated urachal structures. The contralateral bladder pedicle should be preserved because the ipsilateral bladder pedicles will have been divided while mobilizing the ureter. On adequate mobilization of the bladder, a psoas hitch or a Boari flap can be performed to allow for a tension-free ureterovesical anastomosis.

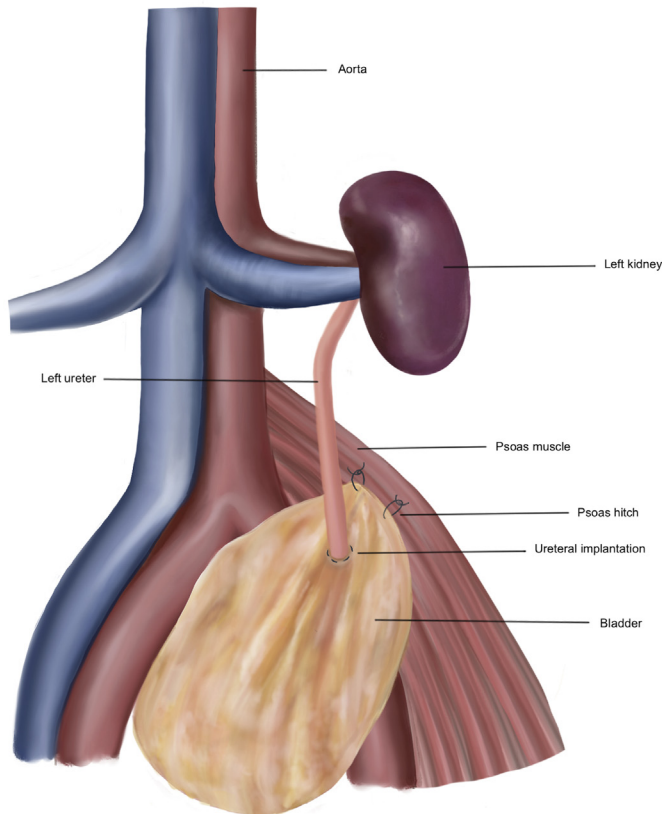
For a psoas hitch, 2-0 polyglactin 910 suture is used to hitch the bladder superiorly to the psoas tendon with special care taken to avoid the genitofemoral and ilioinguinal nerves. Once the bladder is appropriately fixed, the surgeon proceeds to ureteral reimplantation, using either running or interrupted sutures. A 1.5-cm incision is made through the bladder muscle and mucosa. Once half of the anastomosis is complete, a double-J ureteral stent is placed. A guidewire is placed through the assistant's trocar and up the ureter. The proximal end of the stent is advanced up the ureter using robotic arms. The guidewire is then removed and the robotic arms are used to insert the distal end of the stent into the bladder without need for a guidewire. The anastomosis is then completed (Fig. 8). Anastomosis patency can be tested by filling the bladder.

## ROBOT-ASSISTED SEGMENTAL URETERECTOMY WITH PRIMARY URETEROURETEROSTOMY

Robot-assisted segmental ureterectomy with ureteroureterostomy is considered for mid-ureteral tumors. Ideal candidates have low-grade, mid-ureteral tumors that are not amenable to endoscopic ablation.<sup>31</sup> High-grade tumors are treated with this approach when there is a solitary kidney or poor renal function, and distal ureterectomy is not technically feasible. The preoperative evaluation must include ureteroscopy of the collecting system, which is preserved to ensure that the urothelium is free of visible cancer.

The patient is positioned on the operating table in lateral decubitus position with ipsilateral side up.<sup>32</sup> Patient positioning and trocar placement is the same as described for robotic nephroureterectomy. A urinary catheter is inserted into the bladder. On entry into the abdomen, the colon should be mobilized and the white line of Toldt incised to expose the retroperitoneum. The ureter should be visualized, and the tumor may be located based on its bulging appearance. However, if tumor location is not completely clear, a ureteroscope may be advanced over a guidewire to locate the ureteral tumor as described for robotic distal ureterectomy. The surgeon should then be able to identify the location of the ureteral tumor laparoscopically from the light emitted by the ureteroscope. Once the ureter has been sufficiently mobilized to completely excise the tumor and perform a tension-free anastomosis, the ureter can be clipped above and below the tumor to minimize the risk of tumor spillage. Proximal and distal margins are sent for frozen section before proceeding with ureteroureterostomy. The surgeon ensures that the ureteral ends may be anastomosed in a tension-free manner. Ureteral resections larger than 2 cm may require a more complex reconstruction, such as ileal interposition.<sup>32</sup> A segmental ureterectomy may be the best option for a small high-grade ureteral tumor with a solitary kidney; lymphadenectomy in the draining lymph area is performed for high-grade tumors. For the primary ureteroureterostomy, the proximal and distal ends of the divided ureter should be spatulated on opposing sides by 1 cm and stay sutures should be placed on each end. Care must be taken to avoid twisting the ureteral ends during this process. The ureteral ends are then positioned so that the spatulated side of one ureter is sewn to the unspatulated side of the other ureteral end. A stent is placed after the first side of the anastomosis is complete, the ureter is flipped, and the anastomosis is completed.





**Fig. 8.** Reimplantation of ureter onto bladder with psoas hitch following distal ureterectomy.

## SUMMARY

Upper tract UC is a rare malignancy for which surgery provides definitive management. Open radical nephroureterectomy was the gold standard treatment, but laparoscopic and robot-assisted approaches are alternative options. Kidney-sparing approaches are feasible for carefully selected patients with ureteral cancer.

## DISCLOSURES

The authors have no disclosures to make.

## REFERENCES

1. Jemal A, Siegel R, Ward E, et al. Cancer statistics, 2009. *CA Cancer J Clin* 2009;59(4):225–49.
2. Raman JD, Messer J, Sielatycki JA, et al. Incidence and survival of patients with carcinoma of the ureter and renal pelvis in the USA, 1973–2005. *BJU Int* 2011;107(7):1059–64.
3. Kakizoe T. Development and progression of urothelial carcinoma. *Cancer Sci* 2006;97(9):821–8.
4. Honda Y, Nakamura Y, Teishima J, et al. Clinical staging of upper urinary tract urothelial carcinoma for T staging: review and pictorial essay. *Int J Urol* 2019;26(11):1024–32.
5. Amin MB, Edge SB. *AJCC cancer staging manual*. New York: Springer; 2017.
6. Hall MC, Womack S, Sagalowsky AI, et al. Prognostic factors, recurrence, and survival in transitional cell carcinoma of the upper urinary tract: a 30-year experience in 252 patients. *Urology* 1998; 52(4):594–601.
7. Clayman RV, Kavoussi LR, Figenschau RS, et al. Laparoscopic nephroureterectomy: initial clinical case report. *J Laparoendosc Surg* 1991;1(6):343–9.
8. Ni S, Tao W, Chen Q, et al. Laparoscopic versus open nephroureterectomy for the treatment of upper urinary tract urothelial carcinoma: a systematic review and cumulative analysis of comparative studies. *Eur Urol* 2012;61(6):1142–53.
9. Margulis V, Shariat SF, Matin SF, et al. Outcomes of radical nephroureterectomy: a series from the upper tract urothelial carcinoma collaboration. *Cancer* 2009;115(6):1224–33.
10. Klingler DW, Hemstreet GP, Balaji K. Feasibility of robotic radical nephrectomy: initial results of single-institution pilot study. *Urology* 2005;65(6): 1086–9.

11. Ludwig WW, Gorin MA, Pierorazio PM, et al. Frontiers in robot-assisted retroperitoneal oncological surgery. *Nat Rev Urol* 2017;14(12):731–41.
12. Clements MB, Krupski TL, Culp SH. Robotic-assisted surgery for upper tract urothelial carcinoma: a comparative survival analysis. *Ann Surg Oncol* 2018;25(9):2550–62.
13. Rodriguez JF, Packiam VT, Boysen WR, et al. Utilization and outcomes of nephroureterectomy for upper tract urothelial carcinoma by surgical approach. *J Endourol* 2017;31(7):661–5.
14. Hemal AK, Nayyar R, Gupta NP, et al. Experience with robot assisted laparoscopic surgery for upper and lower benign and malignant ureteral pathologies. *Urology* 2010;76(6):1387–93.
15. Roupêt M, Babjuk M, Comperat E, et al. European guidelines on upper tract urothelial carcinomas: 2013 update. *Eur Urol* 2013;63(6):1059–71.
16. De Groote R, Decaestecker K, Larcher A, et al. Robot-assisted nephroureterectomy for upper tract urothelial carcinoma: results from three high-volume robotic surgery institutions. *J Robot Surg* 2020;14(1):211–9.
17. Lenis AT, Donin NM, Faiena I, et al. Role of surgical approach on lymph node dissection yield and survival in patients with upper tract urothelial carcinoma. Paper presented at: *Urologic Oncology: Seminars and Original Investigations*, 2018.
18. Fukushima H, Saito K, Ishioka J, et al. Equivalent survival and improved preservation of renal function after distal ureterectomy compared with nephroureterectomy in patients with urothelial carcinoma of the distal ureter: a propensity score-matched multicenter study. *Int J Urol* 2014;21(11):1098–104.
19. Dalpiaz O, Ehrlich G, Quehenberger F, et al. Distal ureterectomy is a safe surgical option in patients with urothelial carcinoma of the distal ureter. Paper presented at: *Urologic Oncology: Seminars and Original Investigations*, 2014.
20. Jeldres C, Lughezzani G, Sun M, et al. Segmental ureterectomy can safely be performed in patients with transitional cell carcinoma of the ureter. *J Urol* 2010;183(4):1324–9.
21. Seisen T, Peyronnet B, Dominguez-Escrig JL, et al. Oncologic outcomes of kidney-sparing surgery versus radical nephroureterectomy for upper tract urothelial carcinoma: a systematic review by the EAU non-muscle invasive bladder cancer guidelines panel. *Eur Urol* 2016;70(6):1052–68.
22. Roupêt M, Babjuk M, Compérat E, et al. European Association of Urology guidelines on upper urinary tract urothelial carcinoma: 2017 update. *Eur Urol* 2018;73(1):111–22.
23. Cowan NC, Turney BW, Taylor NJ, et al. Multidetector computed tomography urography for diagnosing upper urinary tract urothelial tumour. *BJU Int* 2007;99(6):1363–70.
24. Messer J, Shariat SF, Brien JC, et al. Urinary cytology has a poor performance for predicting invasive or high-grade upper-tract urothelial carcinoma. *BJU Int* 2011;108(5):701–5.
25. Grossman HB, Natale RB, Tangen CM, et al. Neoadjuvant chemotherapy plus cystectomy compared with cystectomy alone for locally advanced bladder cancer. *N Engl J Med* 2003;349(9):859–66.
26. International Collaboration of Trialists. International phase III trial assessing neoadjuvant cisplatin, methotrexate, and vinblastine chemotherapy for muscle-invasive bladder cancer: long-term results of the BA06 30894 trial. *J Clin Oncol* 2011;29(16):2171.
27. Taylor BL, Scherr DS. Robotic nephroureterectomy. *Urol Clin* 2018;45(2):189–97.
28. Chapman TN, Sharma S, Zhang S, et al. Laparoscopic lymph node dissection in clinically node-negative patients undergoing laparoscopic nephrectomy for renal carcinoma. *Urology* 2008;71(2):287–91.
29. Uberoi J, Harnisch B, Sethi AS, et al. Robot-assisted laparoscopic distal ureterectomy and ureteral reimplantation with psoas hitch. *J Endourol* 2007;21(4):368–73.
30. Glinianski M, Guru KA, Zimmerman G, et al. Robot-assisted ureterectomy and ureteral reconstruction for urothelial carcinoma. *J Endourol* 2009;23(1):97–100.
31. McClain PD, Mufarrij PW, Hemal AK. Robot-assisted reconstructive surgery for ureteral malignancy: analysis of efficacy and oncologic outcomes. *J Endourol* 2012;26(12):1614–7.
32. Aboumohamed AA, Ghavamian R. Distal and segmental ureterectomy. In: *Urothelial malignancies of the upper urinary tract*. New York: Springer; 2018. p. 171–7.